



Filtek™

Universal Restorative

About the Case

A 40-year-old male patient was unhappy with the discolouration on his maxillary right lateral incisor that appeared after endodontic treatment. An internal bleaching treatment had not resulted in the desired outcome, so a restorative treatment was needed to obtain a tooth shade similar to that of the adjacent teeth.

Challenge

The patient refused to accept any treatment procedure that involved a conventional tooth preparation, such as a ceramic veneer. The available space was scarce and it clearly wouldn't accommodate a conventional composite in the thickness required to mask the discolouration. The use of 3M™ Filtek™ Universal Restorative Shade A1 and the Pink Opaquer seemed promising. It was hoped this solution would help overcome the challenge of working with thin layers and still mask the discoloured tooth structure.

Outcome

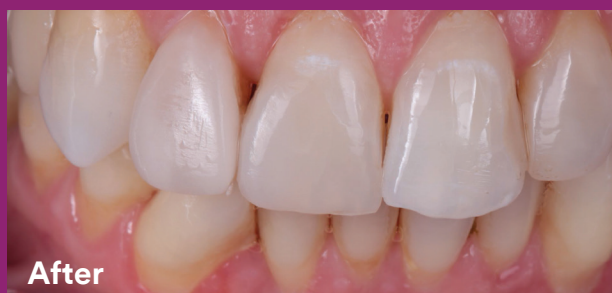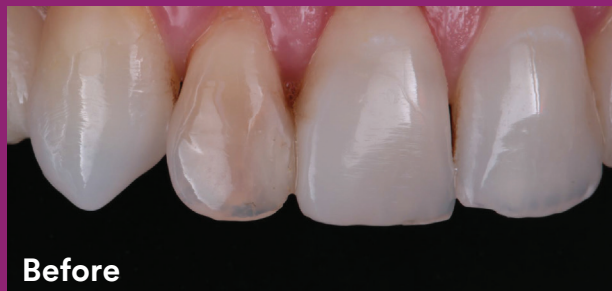The patient was happy with the final result of the treatment. Even with a very thin layer of Pink Opaquer, it was possible to mask the discolouration. The layer thickness of the Pink Opaquer can be increased to 1 millimeter in cases with more severe discolourations.



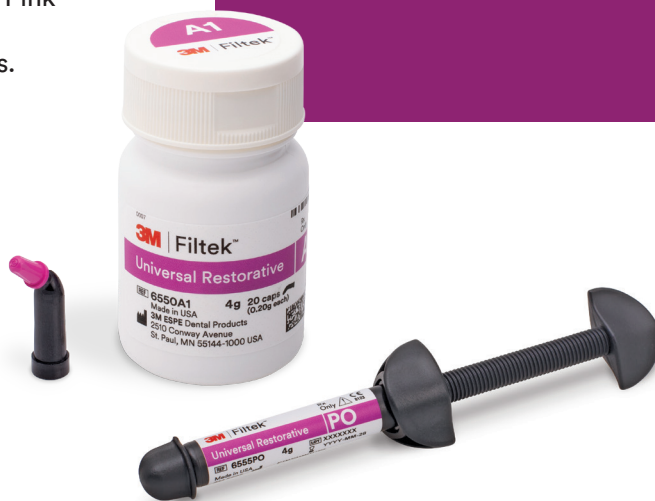Clinical Case
Dr Paulo Monteiro

Non-invasive restorative treatment of a discoloured lateral incisor

Clinical dentistry and photography by Dr Paulo Monteiro



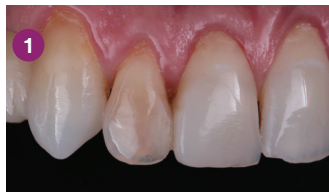See a step-by-step
Case Overview on back.



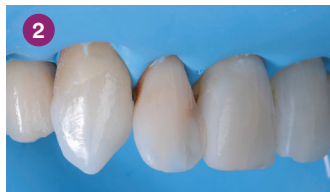About Dr Paulo Monteiro

Dr Paulo Monteiro obtained his doctorate of dental medicine at the Instituto Superior de Ciências da Saúde Egas Moniz (ISCSEM) in Caparica, Portugal, where he developed a passion for aesthetic dentistry. He completed the postgraduate program in Aesthetic and Restorative Dentistry at ISCSEM in 2005. Dr Monteiro is coordinator of and professor in the restorative postgraduate program, Aesthetic and Restorative Dentistry, at Instituto Universitário Egas Moniz. He has an exclusive dental practice in Lisbon that focuses on aesthetic and cosmetic dental treatments.

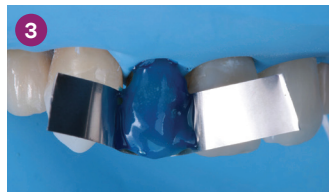Case Overview



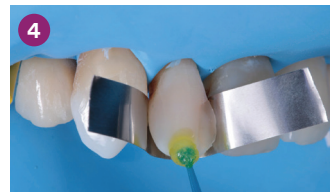1
Initial situation: Frontal view of the upper jaw with an internally discoloured maxillary right lateral incisor that followed endodontic treatment.



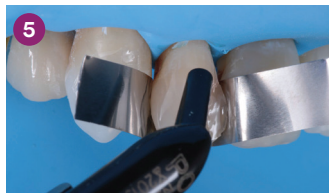2
The working field was isolated. The surface of the lateral incisor was blasted with the 3M™ CoJet™ System, in order to create a micro-retentive structure best for bonding.



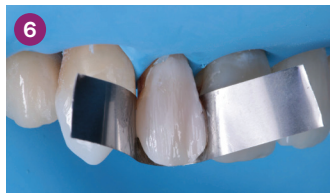3
The roughened enamel was etched with 3M™ Scotchbond™ Universal Etchant for 15 seconds. In order to protect the adjacent teeth from the etching gel, a metal matrix strip was placed.



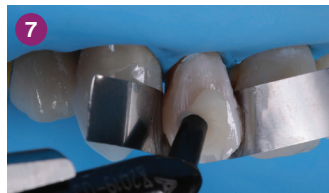4
3M™ Scotchbond™ Universal Adhesive was placed. As recommended by the manufacturer, the product was rubbed into the tooth surface for 20 seconds, treated with a gentle stream of air until the layer appeared rigid and light cured for 10 seconds.



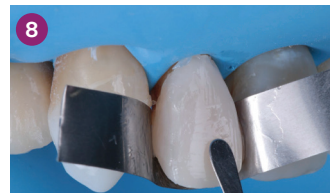5
A very thin layer of the Pink Opaquer was placed and light cured for 20 seconds. The material has a relatively high viscosity and was complimented by 3M™ Filtek™ Universal Restorative's creamy handling.



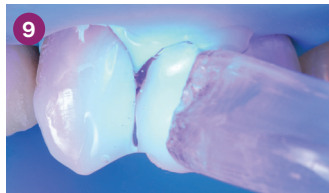
6
Appearance of the tooth after modeling this layer of Pink Opaquer. It could be worked with ease and had minimal layer thickness.



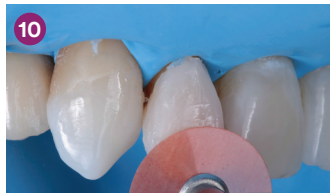7
Filtek Universal Restorative Shade A1 was dispensed from the capsule onto the tooth surface. There was no need to adjust shade selection due to the use of the Pink Opaquer.



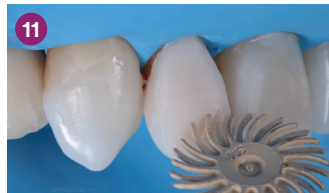8
Modeling of the top layer of composite, which was also very thin.



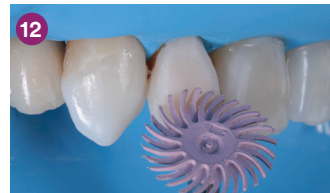9
Restoration was light cured for 20 seconds through a layer of glycerin gel. The gel was used to minimise the formation of an oxygen inhibition layer and increase the degree of polymerisation. This, in turn, facilitated surface polishing.



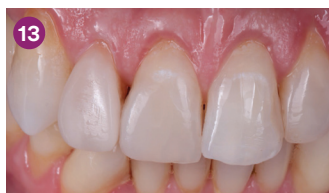10
The restoration was contoured using a 3M™ Sof-Lex™ Extra Thin Finishing and Polishing Disc.



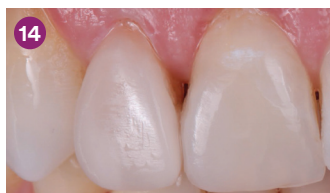11
The restoration surface was polished with the beige pre-polishing spiral of the 3M™ Sof-Lex™ Diamond Polishing System.



12
Final high-gloss polishing was done with the pink diamond polishing spiral of the 3M™ Sof-Lex™ Diamond Polishing System.



13
Treatment outcome: the anterior teeth and the restoration had a similar shade.



14
Final results: Close-up view of the restored lateral incisor.

Refer to Instructions for Use (IFU) for complete product information.

To learn more:

3M.com.au/FiltekUniversal

3M.co.nz/FiltekUniversal

3M

3M Oral Care

3M Australia Pty Limited
Building A, 1 Rivett Road
North Ryde, NSW 2113
1300 363 454
3M.com.au

3M New Zealand Limited
94 Apollo Drive
Rosedale, Auckland 0632
0800 808 182
3M.co.nz



Find us on Facebook

3M, CoJet, Filtek, Scotchbond and Sof-Lex are trademarks of 3M. Please recycle.
© 3M 2019. All rights reserved.